

## Case Report:

### Gardner's syndrome presenting as duodenal carcinoma in a young male

Y.S. Sarma,<sup>1</sup> G. Bhaskararao,<sup>2</sup> M. Sriharibabu,<sup>1</sup> Samir Ranjan Nayak,<sup>2</sup> T. Satyaprakash<sup>3</sup>

Departments of <sup>1</sup>Medicine, <sup>2</sup>Surgery, <sup>3</sup>Pathology, GSL Medical College and General Hospital, Rajahmundry

#### ABSTRACT

Gardner's syndrome (GS) is a variant of familial adenomatous polyposis (FAP) and presents with both colonic and extra colonic manifestations. It is an autosomal dominant disorder and results from mutations in adenomatous polyposis coli (APC) gene. Patients with GS if not treated early will invariably develop colonic cancers at a much younger age than those with sporadic colonic carcinoma. These patients also develop other malignant tumours like duodenal cancers, gastric cancer, hepatoblastoma, papillary carcinoma of the thyroid and multifocal cholangiocarcinomas. With early diagnosis and treatment of colonic polyposis, adenocarcinoma of the duodenum has become the leading cause of death in FAP patients. The mean age at which duodenal carcinoma is diagnosed in FAP is 45-52 years. We report the rare occurrence of duodenal carcinoma as the presenting feature of Gardner's syndrome in a young 25-year-old male with no obvious malignant changes in the colonic adenomas.

**Key words:** Adenomatous polyposis, Gardner syndrome, Adenomatous polyposis coli gene, Duodenal neoplasm

Sarma YS, Bhaskararao G, Sriharibabu M, Nayak SR, Satyaprakash T. Gardner's syndrome presenting as duodenal carcinoma in a young male. *J Clin Sci Res* 2015;4:296-300. DOI: <http://dx.doi.org/10.15380/2277-5706.JCSR.14.029>

#### INTRODUCTION

In 1951, Gardner described the occurrence of familial adenomatous polyposis (FAP) with the extra-colonic manifestations of intestinal polyposis, desmoids tumours, osteomas, and epidermoid cysts and hence the eponym Gardner's syndrome.<sup>1-3</sup> Congenital hypertrophy of the retinal pigmented epithelium (CHRPE), dental abnormalities, benign cystic lung tumours and lymphoid hyperplasia of the terminal ileum are the other manifestations of Gardner's syndrome. It is an autosomal dominant condition caused by a mutation in the adenomatous polyposis coli (APC) tumour-suppressor gene.<sup>1-3</sup> Patients with Gardner's syndrome if not treated early will invariably develop colonic cancers at a much younger age than those with sporadic colonic carcinoma.<sup>4</sup> Besides colorectal cancers, these patients also develop other malignant tumours like

periampullary adenocarcinoma, hepatoblastoma, papillary carcinoma of the thyroid and multifocal cholangiocarcinomas.<sup>5</sup> The location and type of the mutation on the APC gene that determines the phenotypic variations in the presentation of FAP. The number of adenomatous polyps in FAP can range from few hundred to several thousands and the cancer risk increases in proportion to the number of polyps detected at colonoscopy.<sup>6</sup> Early diagnosis of FAP is important to prevent the later complications associated with this syndrome. Here we are presenting a rare case of FAP who presented with adenocarcinoma of distal duodenum and proximal jejunum.

#### CASE REPORT

A 25-year-old male individual, a lorry cleaner by occupation was admitted to our hospital with four months history of intermittent abdominal cramps, diarrhoea, vomiting and passage of

Received: May 09,2014; Revised manuscript received: March 27, 2015; Accepted:April 09, 2015.

**Corresponding author:** Dr M. Sriharibabu, Professor, Department of Medicine, GSL Medical College and General Hospital, Rajahmundry, India.  
**e-mail:** manne.sappu@gmail.com

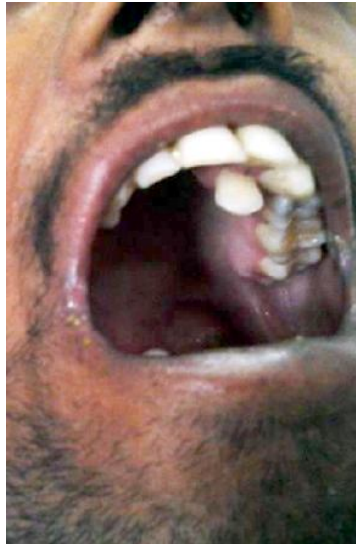

#### Online access

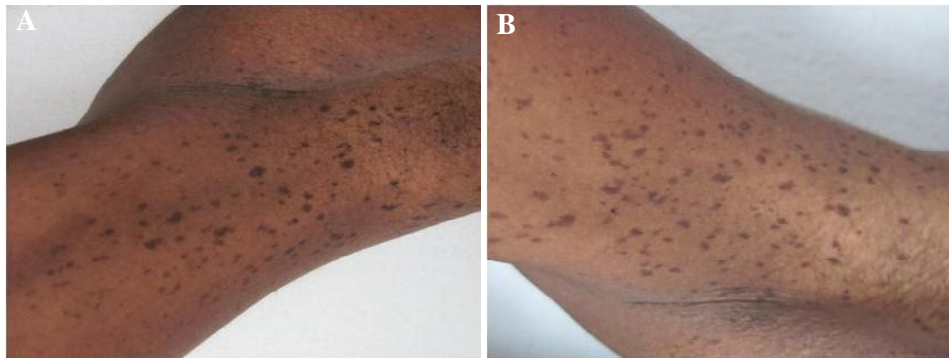
[http://svimstpt.ap.nic.in/jcsr/Oct-dec15\\_files/2cr15.pdf](http://svimstpt.ap.nic.in/jcsr/Oct-dec15_files/2cr15.pdf)  
DOI: <http://dx.doi.org/10.15380/2277-5706.JCSR.14.029>

blood and mucous in stools. Initially he was treated by a local practitioner and was relieved of his symptoms. As patient had further experienced repeated attacks of pain he got admitted to our hospital for evaluation. On physical examination, the patient was thinly built. Moderate anaemia was evident. His pulse

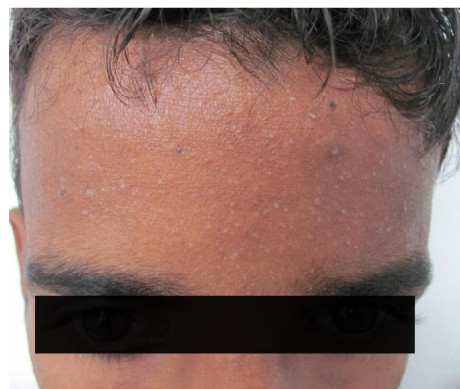was 87/min and blood pressure was 110/70 mm of mercury. Patient had dolicocephaly with malaligned teeth (Figure 1) and hyperpigmentation of both axillae (Figure 2) and oral mucosal surface. A nevus was seen at the inner canthus of the left eye and multiple sebaceous cysts were seen over the face (Figure 3). There



**Figure 1:** Clinical photograph showing malaligned teeth



**Figure 2:** Clinical photograph showing hyperpigmentation of Right (A) and left axilla (B)

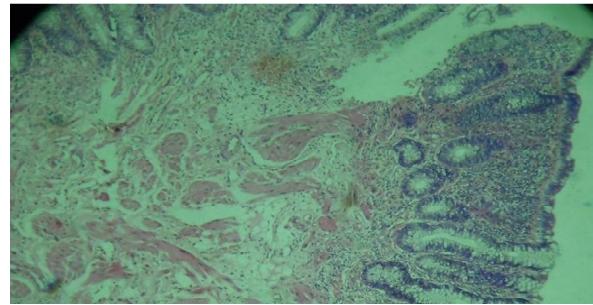


**Figure 3:** Clinical photograph showing multiple sebaceous cysts on the face

was a palpable mass in the left hypochondrium which was firm to hard in consistency. Computed tomography of the (CT) abdomen revealed matted small bowel loops forming a mass measuring 7 x 7 cm in the left hypochondriac region. Radiograph of the skull revealed osteomas in the frontal bone. Fundus examination did not reveal CHRPE. CT brain revealed a ventricular cyst. Upper gastrointestinal (GI) endoscopy revealed multiple polyps extending from gastro-oesophageal junction to duodenum. Colonoscopy revealed multiple polyps, few hundreds in number extending from rectum to ascending colon. On histo-pathological examination of biopsy specimen both colonic and gastric polyps were found to be adenomatous polyps (Figure 4). Exploratory laparotomy revealed a mass lesion involving fourth part of the duodenum, proximal jejunum which was fixed to the pancreas and encasing aorta, superior mesenteric artery and vein (Figure 5). Regional lymphadenopathy and multiple liver metastases were evident. Fine needle aspiration cytology (FNAC) smears from the lymph nodes and liver metastasis confirmed the presence of adenocarcinoma (Figure 6). The final diagnosis was Gardner's syndrome with duodenal adenocarcinoma stage IV.

## DISCUSSION

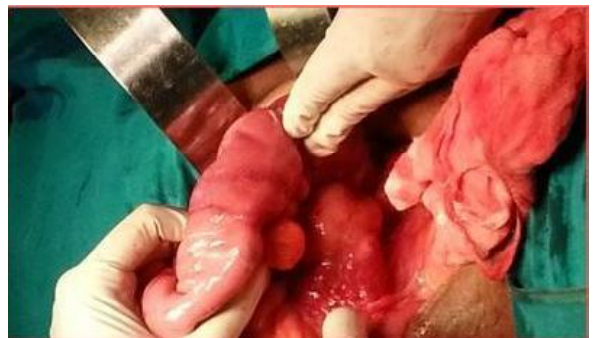Gardner's syndrome is an uncommon variant of FAP with uniform worldwide distribution involving one in 8000-14000 live births. It equally affects both genders. Most patients manifest clinical symptoms by the age of 20 years and if not recognized early they invariably develop colonic cancer by the age of 40 years.<sup>6</sup> Emphasis on family history and attention to extra-colonic manifestations of GS will give clues to early diagnosis. Sigmoidoscopy and colonoscopy will add to the diagnosis by demonstrating multiple polyps (varying between 100 to a few thousands) in the rectum



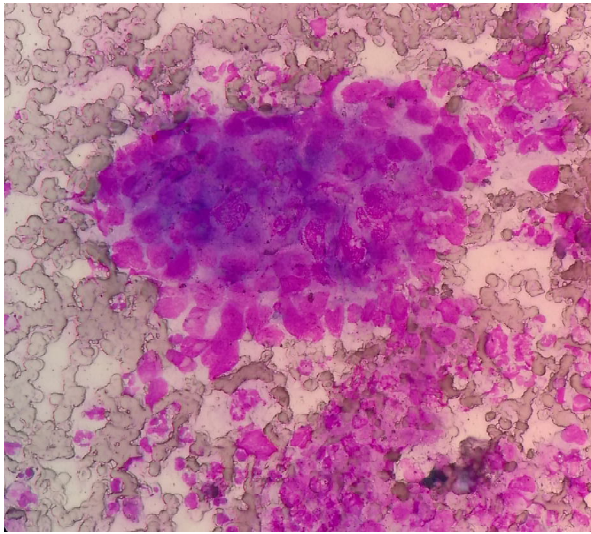
**Figure 4:** Photomicrograph of colonoscopic biopsy showing features suggestive of colonic tubular adenoma (Haematoxylin and eosin,  $\times 100$ )

and colon. Molecular genetic testing for adenomatous polyposis coli (APC) gene mutations will confirm the diagnosis and is most often used in the early diagnosis of at-risk family members. Extra-colonic manifestations of GS vary from person to person. All the extra-colonic manifestations may not be evident in the same individual as the expression of GS is incomplete or partial in many cases.<sup>7,8</sup>

Our patient had dolicocephaly with bony osteomas in the frontal bone and, malaligned teeth in the upper jaw. Hyperpigmentation of axillae, oral mucosa, nevus in left eye and multiple sebaceous cysts on face were the mucocutaneous manifestations. Both colonoscopy and upper GI endoscopy revealed several hundred sessile polyps which were found to be adenomatous polyps on histopathological examination. On clinical examination, we suspected desmoid tumour in the left hypochondrium as the mass was firm in consistency but CT of the abdomen revealed



**Figure 5:** Intraoperative photograph showing the duodenal tumour



**Figure 6:** Photomicrograph of FNAC from metastatic lesion in the liver showing discreetly scattered large round to oval cells with dense basophilic vacuolated cytoplasm and pleomorphic hyperchromatic nuclei with high nuclear-to-cytoplasm ratio and some showing prominent nucleoli suggestive of adenocarcinomatous metastatic deposits (Leishman,  $\times 400$ )

FNAC = fine needle aspiration cytology

that it was due to matted bowel loops. Exploratory laparotomy revealed an inoperable mass involving the fourth part of duodenum and proximal jejunum with hepatic metastasis (Figure 5). None of the family members (parents, brother and sister) had any clinical evidence suggestive of this disorder. As neither parent of the patient had any clinical evidence of this disorder a *de novo* mutation cannot be ruled out in this case.

The usual treatment advised at diagnosis for FAP with more than 100 adenomatous polyps is surgery considering the malignant potential of this condition. More over 25% of symptomatic patients may have cancer at diagnosis. Treatment options include colectomy with ileorectal anastomosis when there are very few polyps in rectum, restorative proctocolectomy with ileal pouch anal anastomosis (IPAA) and total proctocolectomy with ileostomy. Upper gastrointestinal tract surveillance (oesophagogastroduodenoscopy) every 1-3 years is also important in patients with Gardner's syndrome as they may develop

duodenal and gastric carcinomas. In the Heidelberg Polyposis Register, out of 231 cases of FAP monitored with Oesophagogastroduodenoscopy only four cases had duodenal cancer.<sup>9</sup> Lifelong follow-up is necessary as these patients are at increased risk for developing thyroid and pancreatic cancers, brain tumours and hepatoblastoma.<sup>10</sup> As our patient had advanced inoperable stage IV duodenal cancer palliative gastrojejunostomy was done to relieve the symptoms. Histopathological examination of the hepatic metastasis revealed adenocarcinoma and the patient is presently on palliative chemotherapy with cisplatin and 5-fluorouracil (5FU) based regimen.

Primary malignant tumours of the duodenum are rare and account for less than 1% of the GI tumours but at the same time they comprise 50% of the small bowel tumours. The most frequent tumour of the duodenum is an adenocarcinoma. The life time risk for small bowel tumours in FAP is 4% to 12% with majority of them being duodenal carcinomas. With early diagnosis and treatment of colonic polyposis, adenocarcinoma of the duodenum has become the leading cause of death in FAP patients. The mean age at which duodenal carcinoma is diagnosed in FAP is 45-52years.<sup>11</sup> In the present case duodenal carcinoma was the presenting problem of FAP and occurred at an early age of 25 years with no obvious malignant changes in the colonic adenomas.

## REFERENCES

1. Fotiadis C1, Tsekouras DK, Antonakis P, Sfiniadakis J, Genetzakis M, Zografos GC. Gardner's syndrome: A case report and review of the literature. *World J Gastroenterol* 2005;11:5408-11.
2. Mohandas KM. Colorectal cancer in India: controversies, enigmas and primary prevention. *Indian J Gastroenterol* 2011;30:3-6.
3. Singh K1, Singh A2, Kumar P3, Gupta N. Prosthodontic management of a patient with

- Gardner's syndrome: a clinical case report. *Dent Res J (Isfahan)* 2014;11:276-80.
4. Panjwani S, Bagewadi A, Keluskar V, Arora S. Gardner's Syndrome. *J Clin Imaging Sci* 2011;1:65.
  5. Choudary A, Wanjari PV, Tushar P. Gardner's syndrome the importance of early diagnosis: a case report and review of the literature. *J Indian Acad Oral Med Radiol* 2010;22:151-5.
  6. Mitra H, Seyed AT, Majid H, Farzaneh S. A case report of Gardner's syndrome and a review of literature. *Iranian J Pathol* 2010;5:158-62.
  7. Soravia C1, Berk T, Madlensky L, Mitri A, Cheng H, Gallinger S, et al. Genotype-phenotype correlations in attenuated adenomatous polyposis Coli. *Am J Hum Genet* 1998;62:1290-301.
  8. Smud D, Augustin G, Kekez T, Kinda E, Majerovic M, Jelincic Z. Gardner's syndrome: genetic testing and colonoscopy are indicated in adolescents and young adults with cranial osteomas: a case report. *World J Gastroenterol* 2007;13:3900-3.
  9. Kadmon M1, Tandara A, Herfarth C. Duodenaladenomatosis in familial adenomatous polyposis coli. A review of the literature and results from the Heidelberg Polyposis Register. *Int J Colorectal Dis* 2001;16:63-75.
  10. Gu GL1, Wang SL, Wei XM, Bai L. Diagnosis and treatment of Gardner's syndrome with gastric polyposis: a case report and review of the literature. *World J Gastroenterol* 2008;13:2121-3.
  11. Lee CC, Ng WK, Lin KW, Lai TW, Li SM. Adenocarcinoma of the duodenum. *Hong Kong Med J* 2008;14:67-9.