

Autopsy findings in deaths following severe acute respiratory syndrome coronavirus 2 vaccination

Padmavathi Devi Chaganti,¹ Kaumudi Konkay,² Maruthi Devi Karri,¹ Geetha Vani Panchakarla,¹ Vijaya Sree Mandava¹

¹Department of Pathology, Guntur Medical College, Guntur, ²Department of Pathology, Siddhartha Medical College, Vijayawada, Andhra Pradesh, India

Abstract

Background: Vaccination has emerged as an effective tool to prevent severe acute respiratory syndrome coronavirus 2 disease (COVID-19). Concerns regarding adverse effects of vaccine are one of the reasons for vaccine hesitancy. One way of addressing the concerns is by studying post-vaccination deaths. This article presents the autopsy findings of the six individuals who died within 6 weeks post-COVID-19 vaccinations.

Methods: This was a retrospective study of autopsies done between January and June 2021 in recipients of COVID-19 vaccination. All the organs were preserved. After adequate fixation, the organs were grossed and sections were taken.

Results: A total of 6 patients who died after receiving COVID-19 vaccine were autopsied during the study period. All six cases had received Covishield® vaccine. All the individuals were aged between 40 and 60 years, with four males and two females. The duration between vaccination and death ranged from 24 h to 11 days. Three cases had pathology in the kidney, two cases showed pathology in the heart and one case showed pulmonary oedema in both lungs.

Conclusions: This article throws light on post-mortem findings of deaths associated with COVID-19 vaccination.

Keywords: Coronavirus disease vaccine deaths, emphysematous pyelonephritis, kidney disease, pulmonary oedema, thromboembolism

Address for correspondence: Dr Kaumudi Konkay, Associate Professor, Department of Pathology, Siddhartha Medical College, Vijayawada - 520 008, Andhra Pradesh, India.

E-mail: kaumudi_9@yahoo.com

Submitted: 20-Jul-2022 **Revised:** 22-Sep-2022 **Accepted:** 23-Sep-2022 **Published:** 16-Feb-2023

INTRODUCTION

The disease caused by the severe acute respiratory syndrome coronavirus 2 (SARS-CoV-2) (COVID-19), had affected several millions of people worldwide and has taken a heavy death toll claiming thousands of lives.^[1] In a rapid search to combat the deadly disease, COVID-19 vaccine has emerged as an effective tool to prevent the disease. The Indian government has made vaccination against COVID-19 free

in India since 16, January, 2021.^[1] Two vaccines, Covishield (which is Oxford-AstraZeneca vaccine manufactured by Serum Institute of India) and Covaxin (which is manufactured by Bharat Biotech Limited), were granted restricted emergency use authorisation by the Central Drugs Standard Control Organization in India. Sputnik-V also got emergency use authorisation in April 2021.^[2] However, initially, the rate of vaccination in India is rather low and

Access this article online

Quick Response Code:



Website:

www.jcsr.co.in

DOI:

10.4103/jcsr.jcsr_147_22

This is an open access journal, and articles are distributed under the terms of the Creative Commons Attribution-NonCommercial-ShareAlike 4.0 License, which allows others to remix, tweak, and build upon the work non-commercially, as long as appropriate credit is given and the new creations are licensed under the identical terms.

For reprints contact: WKHLRPMedknow_reprints@wolterskluwer.com

How to cite this article: Chaganti PD, Konkay K, Karri MD, Panchakarla GV, Mandava VS. Autopsy findings in deaths following severe acute respiratory syndrome coronavirus 2 vaccination. J Clin Sci Res 2023;12:51-6.

not as expected, owing to vaccine hesitancy not only in the general public but also in health-care professionals. Concerns regarding the adverse effects of the vaccine are one of the reasons for vaccine hesitancy.^[3] The main way of addressing the concerns is by studying the adverse reactions, especially the deaths occurring after the vaccinations, which will provide valuable insights about this disease. This paper presents the autopsy findings of the six individuals who died within 6 weeks post-COVID-19 vaccinations.

MATERIAL AND METHODS

This was a retrospective study conducted over a period of 6 months between January 2021 and June 2021. The present study was undertaken in the department of pathology in a tertiary care teaching hospital attached to Guntur Medical College, Guntur, Andhra Pradesh state, in Southern India. The study was approved by the Institutional Ethics Committee (IEC) (IEC No. GMC/IEC/186/2021 dated July, 15/2021). Individuals who received vaccination for COVID-19 and had died within 6 weeks were included in the study. Autopsies unrelated to COVID vaccination were excluded. The instructions to conduct autopsy was given by the District Medical and Health Officer, Government of Andhra Pradesh and Medical Superintendent Government General Hospital (GGH), Guntur. Consent for autopsy was obtained from the immediate relative also. The autopsy was done as per the standard prescribed method followed in the Department of Pathology, Guntur Medical College, Guntur. All the organs were preserved. After adequate fixation, the organs were grossed and sections were taken.

RESULTS

Six patients who died after receiving the COVID-19 vaccine were autopsied during the study period. All of six cases received Covishield vaccine. The demographics, type of vaccine, symptoms, dose of vaccine received and the time period between vaccination and death details of these cases are summarised in Table 1.

Case 1

A 42-year-old accredited social health activist (ASHA) worker received vaccination against COVID-19. The next

day, she developed a high fever; later on the same day, she was shifted to the tertiary care centre for treatment. While undergoing treatment, she died on the 4th day of vaccination. The forensic and pathological autopsy was performed 4 days post-mortem. The autopsy revealed anthracotic pigment in both the lungs with pulmonary oedema/post-mortem congestion of lungs (Figures 1a-d). There was periportal inflammation of the gall bladder, myxomatous degeneration of mitral valve (Figure 2a) and atherosclerotic changes in the aorta. A grey-white nodule was noted in the base of the brain; histopathology showed features of benign meningioma (Figure 2b).

Case 2

A 48-year-old female presented with a recent history of vaccination. Following this, she was admitted to the hospital and died clinically of bilateral pneumonia, diabetic ketoacidosis and left emphysematous pyelonephritis (EPN) on 8th day of admission while undergoing treatment. Her nasopharyngeal swab tested negative for SARS-CoV2 by real-time polymerase chain reaction (RT-PCR). The autopsy was performed within 24 h. The external examination revealed ecchymoses of the vaccination site on the right arm, gangrene great toe of the left foot, bed sore of 11 cm × 7 cm in the sacral region. Microscopic findings showed extensive areas of haemorrhage, multiple abscesses and hyalinised glomeruli in the right kidney (Figure 2f). The cut section of aorta showed atheromatous plaques (Figures 1e and 1f). There was no focus of consolidation or inflammation in both lungs.

Case 3

A 58-year-old male received his first dose of COVID-19 vaccination at a primary health centre. He then developed nausea, passed stool, developed breathlessness and vomited fluid. He developed pulmonary oedema, severe anaphylactic reaction and cardiac arrest. He was shifted to the government general hospital. While undergoing treatment, he expired within 24 h of vaccination. The autopsy was conducted 1 day after death, which revealed bilateral contracted granular kidneys with scarring on the right kidney. Microscopic examination showed chronic

Table 1: Details cases according to age, gender, type of vaccine, symptoms, dose of vaccine received and time period between vaccination and death

	Age	Gender	Type of vaccination	Dose	Symptoms	Time period between vaccination and death
Case 1	42	Female	Covishield	1 st dose	Developed high fever on the next day	After 4 days
Case 2	48	Female	Covishield	1 st dose	-	8 days
Case 3	56	Male	Covishield	1 st dose	Severe anaphylaxis	Within 24 h
Case 4	60	Male	Covishield	-	Fell ill after 24 h	24 h
Case 5	47	Male	Covishield	2 nd dose	Fell ill within 8 days	After 11 days
Case 6	45	Male	Covishield	1 st dose	24 h	<24 h

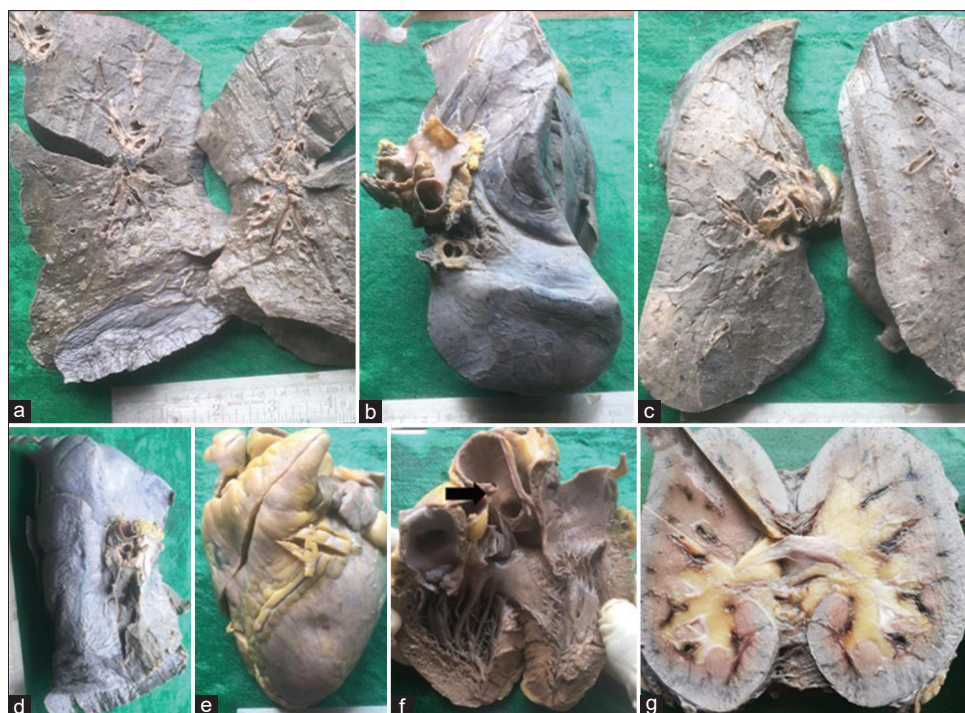

Figure 1: Gross specimen photographs (a-d) external surface and cut - section of the lung in case 1 showing pulmonary oedema. External surface (e) and cut section of heart (f) showing atherosclerotic changes in the aorta (arrow) in case 2. Cut-section of kidneys of case 6 showing oedema and haemorrhages at the corticomedullary junction, microscopy revealed acute tubular necrosis (g)

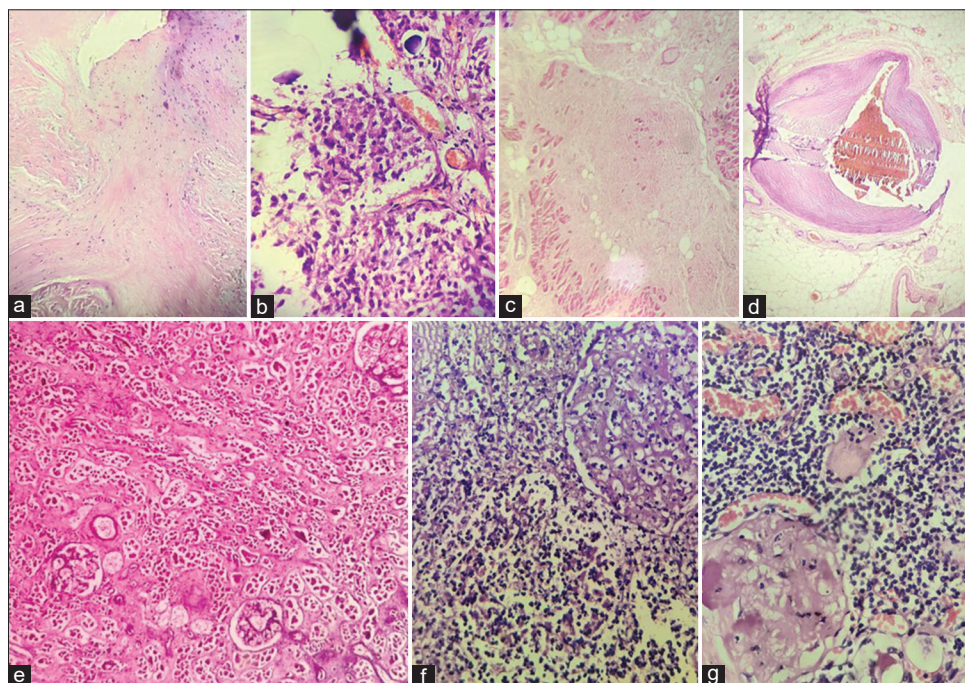


Figure 2: Photomicrograph of mitral valve (Case 1) showing myxomatous change (Haematoxylin and eosin, $\times 100$) (a). Photomicrograph showing cells in nests, psammomatous calcifications suggestive of meningioma (Case 1) (Haematoxylin and eosin, $\times 400$) (b). Photomicrograph of interventricular septum (Case 4) showing fibrosis (Haematoxylin and eosin, $\times 100$) (c). Photomicrograph of coronary artery (Case 4) showing luminal narrowing and intraluminal thrombus (Haematoxylin and eosin, $\times 40$) (d). Photomicrograph of kidney (Case 6) showing acute tubular necrosis (Haematoxylin and eosin, $\times 100$) (e). Photomicrograph of kidney (Case 2) showing collections of neutrophils and infarcted glomerulus suggestive of emphysematous pyelonephritis (Haematoxylin and eosin, $\times 400$) (f). Photomicrograph of kidney (Case 3) showing hyalinised glomerulus and interstitial lymphocytic infiltrate suggestive of chronic pyelonephritis (Haematoxylin and eosin, $\times 400$) (g)

pyelonephritic changes in both the kidneys (Figure 2g), sections from both the lungs show dilated congested vessels and evidence of emphysematous changes, and atherosclerotic changes in the aorta.

Case 4

A 60-year-old male who got vaccinated for COVID-19 at a nearby local hospital, fell ill in the early hours of the next day. His family members shifted him to government general hospital, where he died within 24 h of vaccination while undergoing treatment.

The autopsy was performed on the next day of death. External examination showed a 21 cm midline scar on the anterior chest wall. Grossly, the heart showed a stent placed at the origin of left anterior descending (LAD) artery and another stent in the distal segment of the right coronary artery, which is 5 cm in length. Aorta showed atheromatous plaques and both the lungs showed anthracotic pigment. Histopathology revealed the right coronary artery lumen narrowing (Figure 2d), fibrosis of the interventricular septum (Figure 2c) and anterior border of the left ventricle and pulmonary oedema in both the lungs.

Case 5

A 47-year-old male, a police constable by occupation, had taken two doses of COVID-19 vaccination. After 7 days of taking the second dose, he suffered from ill health and stayed at home while taking treatment from nearby PHC. Four days later, he was unable to breathe and his relatives shifted him to a hospital. COVID-19 rapid antigen test had tested positive. He was shifted to COVID-19 care centre, government general hospital. There he died on the same day while receiving treatment, which is after 11 days of vaccination. The autopsy was done 10 days after death which showed features of pulmonary oedema in both the lungs.

Case 6

A 45-year-old male with a history of vaccination developed the illness after 24 h and then died. The autopsy revealed acute tubular necrosis (ATN) in both the kidneys (Figure 1g and 2e). The LAD artery showed an occlusive thrombus and calcifications in the tunica media, left circumflex artery showed narrowing of the lumen. Both lungs showed focal neutrophilic collections in the interstitium along with pigment-laden macrophages in the interstitium.

DISCUSSION

Covishield is an Oxford-AstraZeneca vaccine manufactured by Serum Institute of India and uses the modified, non-replicant chimpanzee adenovirus ChAdOx1

as a vector.^[4] The known adverse effects of this vaccine include thromboembolic complications like intracranial venous sinus thrombosis, and thrombocytopenia (platelet count $<100,000/\text{mm}^3$). In a report,^[4] three patients developed cranial venous sinus thrombosis after the first dose of 'COVID-19 vaccine AstraZeneca' and antibodies were found against platelet factor 4 (CXCL4) in all three of them. The authors of this report^[4] proposed that these antibodies form a complex with the antigen, that is CXCL4 platelet factor; and this complex binds to the platelet membrane's Fcγ-receptor IIa. This leads to the consumption of platelets, which causes thrombocytopenia, and finally, disseminated intravascular coagulation occurs.

We could identify the thromboembolic phenomenon in few of our cases. There were pathologies related to long-term comorbidities in all the cases, but we could not attribute a causal relationship between pathologies identified and known vaccination complications. There is not much literature available on deaths following Covishield vaccine. It has been stated that some vaccine-disease and vaccine-drug interactions can influence patient outcomes negatively in certain susceptible individuals.^[5] We are not certain how much of the patient outcomes can be attributable to the vaccine, as in our first case, we identified meningioma and myxomatous degeneration of mitral valve, but she was previously asymptomatic and apparently healthy.

Our second case had EPN, which is an acute and severe necrotising infection of renal parenchyma with the characteristic presence of gas, along with diabetic ketoacidosis and bilateral pneumonia. EPN with associated diabetic ketoacidosis is very uncommon and 'diabetic ketoacidosis' itself is a bad prognosticator of death in patients with EPN.^[6]

Our third case was clinically diagnosed with anaphylaxis. The Brighton Collaboration case definition criteria for the identification of anaphylaxis include laboratory investigations like mast cell tryptase levels, which unfortunately could not be done at our centre due to a lack of availability of tests.^[7] Raised serum immunoglobulin E levels and post-mortem findings are not pathognomic and so are not included under the Brighton Collaboration case defining criteria for the identification of anaphylaxis. In addition, post-mortem revealed chronic pyelonephritis of both the kidneys and emphysematous changes in the lungs in this case. As ChAdOx1 nCoV-19 (Oxford-AstraZeneca) vaccine is a replication-defective viral-vectored vaccine, it is supposed to be safe in kidney disease patients, and in fact,

some trials are prioritising these patients for vaccination as they are immunocompromised.^[8] The reported rate of anaphylaxis occurring as adverse events following immunisation is <1/million doses for most vaccines.^[9] No anaphylaxis events were reported in clinical trials for the Covishield vaccine.^[9] Tom Shimabukuro described ten cases of anaphylaxis after administration of the first doses of Moderna COVID-19 vaccine, at an estimated rate of 2.5 anaphylaxis cases per million first Moderna COVID-19 vaccine doses administered, and there were no recorded deaths.^[10] CDC identified 21 cases of anaphylaxis following the first doses of the Pfizer-BioNTech COVID-19 vaccine, with a reported rate of anaphylaxis of 11.1 cases per million doses administered.^[10,11] Nevertheless, Covishield ChAdOx1 vaccine contains an allergen named polysorbate 80 at a very low concentration of <100 µg/dose, which is the same as that found in most injected influenza vaccines that are given annually and are not associated with a higher rate of hypersensitivity reactions. That is why Public Health England in the United Kingdom recommends the AstraZeneca Covishield ChAdOx1 vaccine for individuals with Polyethylene glycols allergy.

In our fourth case, there was right coronary artery lumen narrowing and pulmonary oedema in both lungs. The changes could be secondary to left heart failure that might be due to myocardial infarction that have occurred due to a thromboembolic event. However, it is only a hypothesis as there was no direct evidence and the patient had an old heart disease evident by the presence of fibrosis of the interventricular septum and anterior border of the left ventricle.

The fifth case died after 11 days of receiving the vaccine and tested positive for COVID antigen. Hence, his death might as well be due to COVID disease rather than vaccine. The post-mortem finding, in this case, was pulmonary oedema.

The sixth case showed ATN in both kidneys. LAD artery showed occlusive thrombus and calcifications in the tunica media, left circumflex artery showed narrowing of the lumen. Both lungs showed focal neutrophilic collections in the interstitium along with pigment-laden macrophages in the interstitium. ATN could have occurred secondary to circulatory collapse, which might have occurred because of heart failure, as was evidenced by the presence of thrombus in LAD. ATN in COVID-19 is known; however, there are no reports of ATN after the Covishield vaccine.^[12] There are case reports of renal biopsy-proven membranous nephropathy and acute interstitial nephritis following the

2009 H1N1 influenza vaccination, which might have caused activation of the immune system.^[13]

The limitation of this study is that we cannot definitely rule out adverse reactions as causes of death in all the cases. With the growing number of COVID-19 cases worldwide, and anticipation of a third wave globally, mass vaccination is one of the main preventive tools left with us to combat the deadly disease. To achieve better vaccination rates, vaccine hesitancy should be addressed by alleviating fears against adverse vaccine reactions, which can be achieved by a thorough comprehensive analysis of autopsy data of death following COVID-19 vaccination. This article throws light on post-mortem findings of deaths associated with COVID-19 vaccination.

Declaration of patient consent

The authors certify that they have obtained all appropriate patient consent forms. In the form the patient(s) has/have given his/her/their consent for his/her/their images and other clinical information to be reported in the journal. The patients understand that their names and initials will not be published and due efforts will be made to conceal their identity, but anonymity cannot be guaranteed.

Financial support and sponsorship

Nil.

Conflicts of interest

There are no conflicts of interest.

REFERENCES

1. Kumar VM, Pandi-Perumal SR, Trakht I, Thyagarajan SP. Strategy for COVID-19 vaccination in India: The country with the second highest population and number of cases. NPJ Vaccines 2021;6:60.
2. MoHFW. Frequently Asked Questions: COVID-19 Vaccination. New Delhi: Ministry of Health and Family Welfare, Government of India; 2021. Available from URL: <https://www.mohfw.gov.in/pdf/FAQsCOVID19vaccinesvaccinationprogramWebsiteupload27Sep.pdf>. [Last accessed on 2022 Nov 27].
3. Jain J, Saurabh S, Kumar P, Verma MK, Goel AD, Gupta MK, et al. COVID-19 vaccine hesitancy among medical students in India. Epidemiol Infect 2021;149:e132.
4. Wolf ME, Luz B, Niehaus L, Bhogal P, Bärzner H, Henkes H. Thrombocytopenia and Intracranial Venous Sinus Thrombosis after "COVID-19 Vaccine AstraZeneca" Exposure. J Clin Med 2021;10:1599.
5. Lv G, Yuan J, Xiong X, Li M. Mortality rate and characteristics of deaths following COVID-19 vaccination. Front Med (Lausanne) 2021;8:670370.
6. Song Y, Shen X. Diabetic ketoacidosis complicated by emphysematous pyelonephritis: A case report and literature review. BMC Urol 2020;20:6.
7. Rüggeberg JU, Gold MS, Bayas JM, Blum MD, Bonhoeffer J, Friedlander S, et al. Brighton Collaboration Anaphylaxis Working

- Group. Anaphylaxis: Case definition and guidelines for data collection, analysis, and presentation of immunization safety data. *Vaccine*. 2007;25:5675-84.
8. Windpessl M, Bruchfeld A, Anders HJ, Kramer H, Waldman M, Renia L, *et al.* COVID-19 vaccines and kidney disease. *Nat Rev Nephrol* 2021;17:291-3.
9. Turner PJ, Ansotegui IJ, Campbell DE, Cardona V, Ebisawa M, El-Gamal Y, *et al.* COVID-19 vaccine-associated anaphylaxis: A statement of the World Allergy Organization Anaphylaxis Committee. *World Allergy Organ J* 2021;14:100517.
10. Shimabukuro T. Allergic reactions including anaphylaxis after receipt of the first dose of Moderna COVID-19 vaccine – United States, December 21, 2020-January 10, 2021. *Am J Transplant* 2021;21:1326-31.
11. Shimabukuro T, Nair N. Allergic reactions including anaphylaxis after receipt of the first dose of Pfizer-BioNTech COVID-19 vaccine. *JAMA* 2021;325:780-1.
12. Ng JH, Bijol V, Sparks MA, Sise ME, Izzedine H, Jhaveri KD. Pathophysiology and pathology of acute kidney injury in patients with COVID-19. *Adv Chronic Kidney Dis* 2020;27:365-76.
13. Patel C, Shah HH. Membranous nephropathy and severe acute kidney injury following influenza vaccination. *Saudi J Kidney Dis Transpl* 2015;26:1289-93.